

## Histological and Autoradiographic Changes in Locally Irradiated Lymph Nodes (An Experimental Study on Rabbits)

Károly Kett M. D., Tibor Csere\* M. D., László Lukács M. D.,  
Károly Szilágyi M. D. and László Illényi M. D.

1<sup>st</sup> Department Surgery (Chief: Prof. T. Karlinger) and the Roentgenological Clinic\*  
(Chief: Prof. E. Kuhn) of the University Medical School in Pécs/Hungary

### Summary

The authors studied the local effect of 3000 Rxl X-ray irradiation on the popliteal lymph nodes of rabbits. Beside the morpho-histological description autoradiography was performed after injection of H<sup>3</sup>-thymidine in the afferent lymphatic of the irradiated knee node. The main finding is the appearance of newly-formed germinal centers between the 6–10. days after irradiation.

in the lymph node, accompanied by an increased DNA-synthesis (13, 15, 17). Reduced local immune responses after irradiation might be reflected in decreased DNA-production in the lymph node. In the present paper, DNA-synthesis in the irradiated node has been studied at various intervals after irradiation using H<sup>3</sup>-thymidine and autoradiography.

### Introduction:

Lymph nodes play an important role in the immune defence mechanisms probably also in malignancies (4, 7, 8, 9, 10, 15, 17). Therefore, in the planning of the anti-tumor therapy one has to keep in view that the regional lymph nodes are not only a possible site of metastatic dissemination, but also organs involved in immune defence (2, 12).

In order to clear up the problem, numerous authors have already investigated the effect of X-ray irradiation at different dose rates on the regional lymph nodes, primarily by means of morphohistological methods (5, 14). *Teneff and Stoppani* (1953) found by fractionated irradiation with increasing dose rates a gradual lymph node destruction, while *Rutledge and Pletcher* (1958) observed a total destruction and the depletion of lymphoid cells, further the disappearance of germinal centers, under supervolt conditions (5). In rats local irradiation with 3000 R as a single dose leads to a cellular destruction, followed by a rapid repopulation and finally by a delayed regression of the basic tissue structure of the lymph node (*Engeset*, 1966).

Antigenic stimuli elicit cell-renewal and blastoid transformation of lymphocytes

### Material and methods

The investigations were carried out on 63 inbred, white New-Zealand-rabbits, aged 3 months on the average and weighing 3–3,5 kg. The rabbits were held on a standard commercial diet and were of mixed sex. The popliteal nodes of the left hind leg of each animal except 3 rabbits which formed the controls- was exposed to 3000 R X-irradiation in waking state.

The irradiation was performed with a TUR T200 X-ray apparatus operated at 180 keV, 15 mA. 0,5 mm Cu; H.V.L. 1,05 mm Cu. The standard dose was 3000 Rxl measured at the site of the knee node which represented an area of 4x4 cm; elsewhere the animals were shielded with 9 mm lead. The focus-skin distance was about 30 cm. The average dose rate was about 349,3 R/min and the total irradiation time about 8 minutes and 35 seconds.

Measurements of the dose over the neck and the anterior surface of the abdomen and thorax were also made to estimate scattered irradiation related to the whole body. The dose measured over the neck during the irradiation was 2 R, over the abdomen 20 R and the dose over the thorax 12 R.

**Autoradiography:** In order to reduce the costs of the investigation, the animal were given small amounts of high concentrated but low-dosed isotope via the afferent lymphatics of rabbits, into the regional lymph nodes. Autoradiography was performed by the end of the irradiation after 16 hours, daily until the 10<sup>th</sup> day, and on the 30<sup>th</sup> day. At each interval 5 animals were studied. Under i. p. urethane anesthesia an afferent lymphatic to the left knee node was cannulated after visualization with 4% PBV and 50  $\mu$ Ci H<sup>3</sup>-thymidine in 0,1 ml saline (spec. act. 25 Ci/m Mol. Radiochemical Center, Amersham, G. B.) was injected in 2 minutes. An hour later the lymph nodes were cautiously removed, fixed in 4 per cent formol for 24 hours, embedded in paraffin and sectioned. The sections were coated by *Ilford G-4 emulsion* (Ilford Ltd. Ilford, Essex G. B.) and stored at 4° C for two weeks. The unirradiated controls received the same amount of isotope.

### Results

At 16–24 hours after irradiation the follicles are represented only by a narrow ring of lymphocytes, while germinal centers are replaced by granulocytes and a necrotic tissue bulk. The combined thickness of the cortex and paracortex is markedly reduced due to

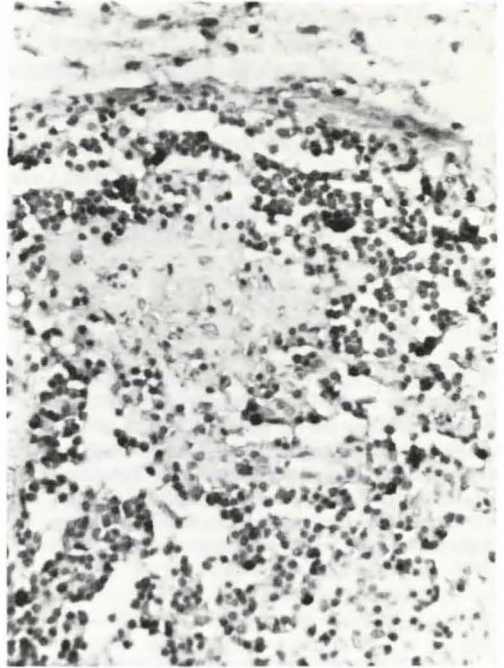


Fig. 1a Autoradiogramme. Rabbit knee node 24 hr. after 3000 Rxl. Lack of normal structure, scattered heavily labelled cells.  
H-E. Magnification ca. 270 x

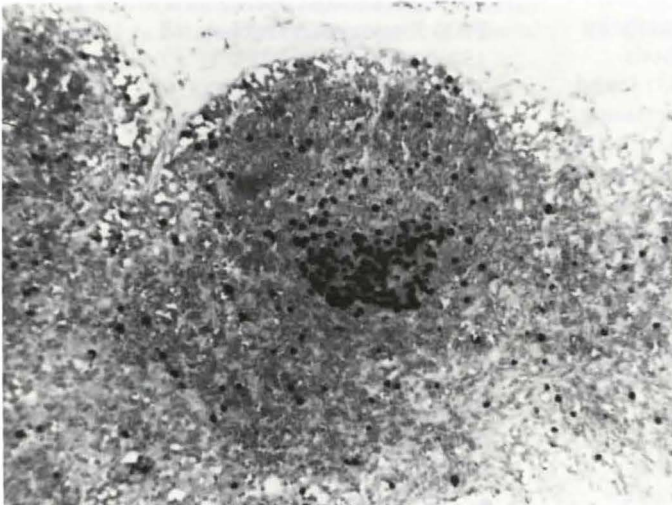


Fig. 1b Autoradiographic view of the cortex from a non-irradiated control node. Agglomeration of labelled cells in a germinal center.  
H-E. Magnification ca. 150 x

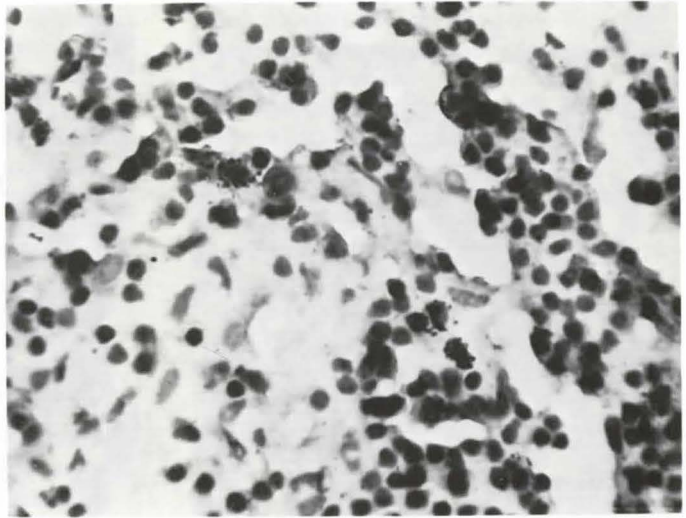


Fig. 2 Autoradiogramme. Rabbit knee node 72 hr. after 3000 Rxl. Lack of germinal centers ("bald follicles"). Labelled cells round the follicles and mostly scattered in the confining zone to the paracortex. H-E. Magnification 460 x

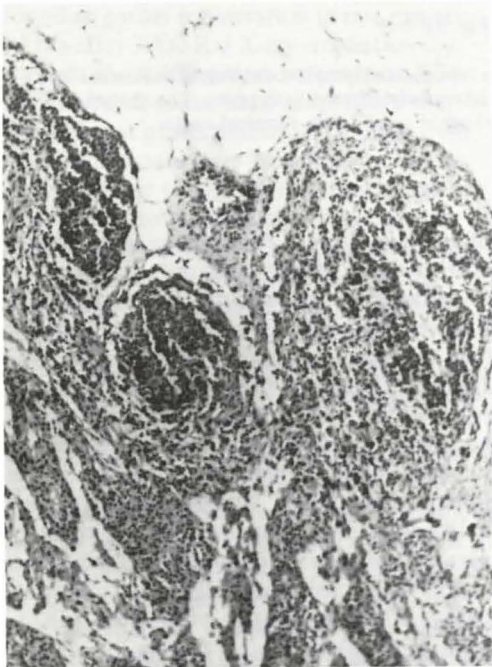

Fig. 3a General view 7 days after irradiation. New follicles situated mostly subcapsular, or bulging into the marginal sinus. Autoradiogramme. H-E. stain. Magnification 150 x

lymphocytic depletion. The destruction of capillary walls is also conspicuous. A diffuse and extremely sparse labelling of cells can be observed over the whole transsection of the node, showing no structural order. (Fig. 1a and 1b)

*48 hours:* The histological picture corresponds to that seen after 24 hours, there are, however, some more labelled cells in the cortex and the medullary area. Germinal centers are absent.

*3. and 4. day:* The basic structure of the lymph nodes is nearly totally disintegrated. On the place of the follicles there are widened capillaries with swollen endothelium and a faint stromal reticulum to be seen. Here and there one can guess very indistinct contours of the follicles. Germinal centers are missing in the histological picture. In the cortex, primarily over the vague contours of follicles, numerous cells became labelled and showed a great density of grains. In the medulla, more specifically in its confining zone against the paracortex and in the adjacent neighbourhood of postcapillary venules labelled cells were arranged in columns. (Fig. 2)

*6. day:* Repopulation is now evident. In some sections there is a discrete agglomeration of

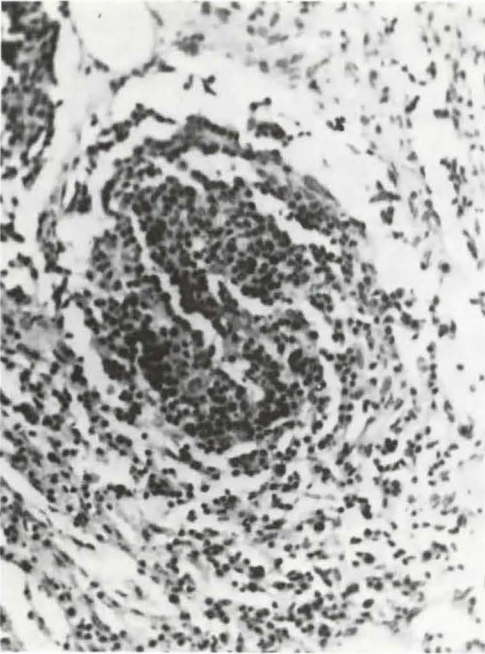


Fig. 3 b

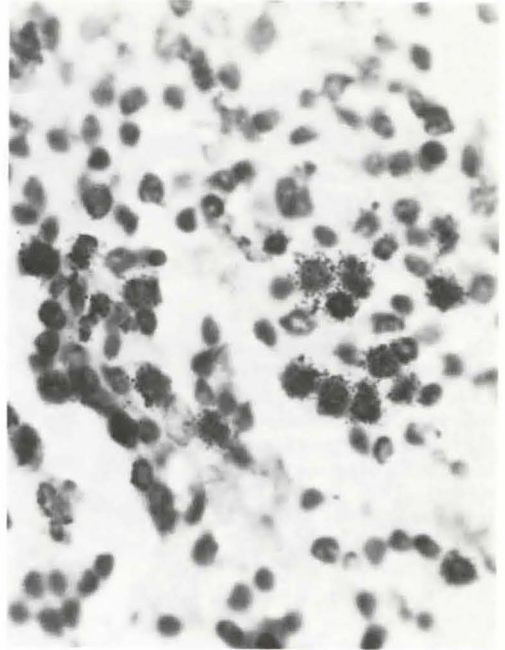


Fig. 3 c

Fig. 3 b, c Autoradiographic picture of a new follicle from a repopulated lymph node. Magnification of Fig. 3 a. Some central cells, mainly of the centro-blastoid type, are intensively covered with grains. The agglomeration of these cells has been observed from the 6. day on and is thought to be a new germinal center. H-E. stain, M. Magnification 300 x and 540 x

cellular elements, hardly identifiable, consisting of macrophages, reticulum cells and plasma cell-like cells, surrounded by a "crown" of lymphoid cells. These newly formed nodules are situated mostly subcapsular, bulging sometimes into the subcapsular marginal sinus. The cortex is narrow in contrast to the widened paracortical area, and the medulla contains numerous plasma cells. Both the cortex and medulla are full of labelled cells, mainly in the marginal zone of the follicles, but also in the field of the new germinal center a marked labelling can be observed.

*7.-8. day:* The new follicles are generally outlined by a marked ring of lymphoid cells. Elsewhere one can find only a few lymphocytes, the walls of the sinuses are swollen and thickened. Most of the follicles are void

of germinal centers. Autoradiography: There is no evidence of distinct germinal centers, surrounded by lymphocytes, which suggest that new germinal centers are being formed. (Fig. 3a, b, c)

*10. day:* The lymph nodes have nearly regained their well-known anatomic structure, but there are few distinct germinal centers. Labelled cells are found predominantly in the follicles and medulla, while labelling is more sparse and without any arrangement in the paracortical zone. The follicles with a bright central area consisting of larger centroblasts always contain a number of labelled cells forming the new germinal centers.

*30. day:* The lymph nodes again have their well defined structure, the paracortical area is widened and characterised by a reticulocytic hyperplasia. Plasma cells are also seen

in a great number while lymphocytes are sparse. The follicles located against the edge of the cortex consist mainly of centroblasts, apart from a narrow ring of lymphocytes. The hyperplasia of reticulum cells reminded us sometimes of the picture of lipomelanotic reticulum. In the medulla there were clusters of plasma cells to be observed. The labelling of cells was similar to that seen after the 10. day.

### Discussion

The main problem emerging at the planning of irradiation therapy is whether an optimal anti-tumor effect can be achieved without influencing the immune defence of the host organism (1, 11, 12). The data obtained in our experiments have been in concordance with the findings of Engeset (5) concluding that 3000 Rxl as a single X-ray dose would cause as a rule a rapid destruction in the nodes irradiated, which will be followed by repopulation and a slow regression process. Engeset found an earlier regeneration in rats namely 24 hrs after 3000 Rxl X-ray irradiation (6). It might show differences between rats and rabbits, but it seems to be more likely that the different protection of the animals from irradiation would have a significance on this point. Engeset placed the rats directly on the lead collimator opening, so the rest of the animal was totally protected. However, doses measured over the anterior surface of the thorax and the abdominal wall – 12 r and 20 r respectively – did not reach 100–300 r to the body, where a significant delay in the repopulation of the node could be expected (3).

Concerning the repopulation, cytokinetic studies speak mainly in favour of the long-recirculating lymphocytes, which can easily be labelled by means of tritiated thymidine. It is however, not to say that our technique would be able to label lymphocytes in the thymus and bone marrow, which might enter the node and repopulate it. Apart from this limitation it seems to be quite suitable to trace early intranodal changes autoradiographically, by means of a small quantity of isotope. The validity of the method has been checked by

giving the same amount of isotope intracutaneously and intranodally. An appreciable labelling was seen only if the isotope had been injected into an afferent lymphatic. These findings have been obtained by the investigation of DNA-metabolism of the knee node in BCG-sensitized rabbits and will be published elsewhere.

The degenerative changes occurring during the regression phase, the diminished barrier-function, further the establishment of collateral lymphatic circuits make the preoperative irradiation of lymph nodes very questionable, and may render the animal susceptible to haematogenous metastases (18, 19, 20).

Direct intralymphatic administration of labelled DNA-precursor in a small amount has yielded some more data about the changes in the regional lymph nodes irradiated with 3000 Rxl. It seems to be very likely that this dose of X-ray – in spite of the rapid destruction process taking place during the first days does not abolish the reactivity of the lymph nodes – moreover, even from the 4. day on after X-ray exposure the renewal and gradual labelling of the T-dependent areas is to be observed, followed soon by the same happenings in the medulla, too.

While the early onset of repopulation could not be demonstrated by the systemic administration of  $H^3$ -thymidine (Engeset, Nesheim (5)) our direct autoradiographic method was capable of tracing the happenings even after 24–72 hrs post irradiationem, which suggested the formation of new follicles mainly next- to the marginal sinus and along the post-capillary venules.

Between the 6. and 10. days the predominance of solid, secondary nodules (16) was found, but there were some other ones with a narrow lymphocytic ring and centrally located centroblastoid cells, too. The labelling of these latter was very intensive and did not differ from the isotope-uptake of germinal centers in non-irradiated controls.

A considerable regression or involution was not seen during the period studied, however, the rate of labelling did not reach the measure of the controls, even after one month.

## References

- 1 *Ceelen, W.*: Die pathologisch-anatomischen Grundlagen des Mammakarzinoms, besonders in Hinblick auf die Strahlenbehandlung. *Strahlentherapie* 87 (1952) 7
- 2 *Crile, G. jr.*: Results of simple mastectomy without irradiation in the treatment of operative stage I. cancer of the breast. *Ann. Surg.* 168 (1968) 330
- 3 *De Bruyn, P. P. H.*: Lymph node and intestinal lymphatic tissue. Chapter 8 in: Bloom, W. ed.: *Histopathology of irradiation from external and internal sources.* McGraw Hill. New York 1948.
- 4 *Engeset, A.*: An experimental study of the lymph node barrier. Injection of Walker carcinoma 256 in the lymph vessels *Acta Un. Int. Cancer* 15 (1958) 897
- 5 *Engeset, A.*: Local irradiation of lymph nodes in rats. *Progr. exp. Tumor Res.* 8 (1966) 225–70
- 6 *Engeset, A.*: Irradiation of lymph nodes and vessels. p. 29–34. *Norwegian Monographs on Medical Science.* Universitetsforlaget, Oslo. 1964.
- 7 *Fischer, B., E. A. Saffer, E. R. Fischer*: Studies concerning the regional lymph node in cancer III. Response of regional lymph node cells from breast and colon cancer patients to PHA stimulation. *Cancer* 30 (1972) 1202
- 8 *Fischer, B., E. A. Saffer, E. R. Fischer*: Studies concerning the regional lymph node in cancer IV. Tumor inhibition by regional lymph node cells. *Cancer* 33 (1974) 631
- 9 *Gardner, B., R. Rosen*: The effect of lymphadenectomy on tumor immunity in the rat. *Surg. Gynecol. Obstet.* 125 (1967) 351
- 10 *Goldfarb, P. M., M. A. Hardy*: The immunologic responsiveness of regional lymphocytes in experimental cancer. *Cancer* 35 (1975) 778
- 11 *Grassberger, A., R. Seyss*: Zur Wirkung der präoperativen Roentgen-Bestrahlung auf die Lymphknoten beim Mammakarzinom. *Strahlentherapie* 118 (1962) 430
- 12 *Kett, K., L. Lukács, T. Csere*: Eine neue Konzeption in der Therapie des Mammakarzinoms. *Brunns' Beiträge* 218/4 (1970) 355
- 13 *Mäkelä, O., G. J. Nossal*: Autoradiographic studies on the immune response. II. DNA synthesis amongst single antibody producing cells. *J. Exp. Med.* 115 (1962) 231
- 14 *Nelson, B., W. Calvo, Th. M. Fliedner, E. Herbst, Chr. Bruch, H.-P. Schnappauf, H.-D. Flad*: The repopulation of lymph nodes after 1200 R whole-body X-irradiation and intravenous administration of mononuclear blood leukocytes. *Am. J. Pathol.* 84/2 (1976) 259
- 15 *Playfair, I. H. L.*: Cell cooperation in the immune response. *Clin. exp. Immunol.* 8 (1971) 839
- 16 *Tjernberg, B.*: Lymphography. An animal study of the diagnosis of V2 carcinoma and inflammation. Uppsala. Almquist and Wiksells, 1962. *Acta Radiol. (Stockholm) Suppl.* 214. 1962.
- 17 *Turk, J. L.*: Lymphocyte response to antigen. A. Afferent side of sensitization arc. (Response of lymphocytes to antigen.) *Transplantation* 5/4 (1967) 952
- 18 *Willis, R. A.*: Pathology of tumors. 3. Edition. Butterworth, London, 1960.
- 19 *Zeidmann, F., J. M. Buss*: I. Effectiveness of the lymph node as a barrier to the passage of embolic tumor cells. *Cancer Res.* 14 (1954) 403
- 20 *Zeidmann, I.*: Experimental studies on the spread of cancer in the lymphatic system. IV. Retrograde spread. *Cancer Res.* 19 (1959) 1114

*K. Kett, M. D., 1<sup>st</sup> Department Surgery of the University Medical School, Pécs/Ungarn*