

## LYMPHANGIOMA ARISING FROM THE OVARY

H.J. Joo, T.J. Lee, S.-H. Lee, E.-J. Lee

Department of Obstetrics and Gynecology (HJ,EL,SL) and Department of Pathology (TL), Chung-Ang University School of Medicine, Seoul, Korea

### ABSTRACT

*Primary lymphangioma arising from the ovary is a rare tumor, with only 24 cases reported to date. As it is often accompanied by ascites or recurrence, similar to a malignant tumor, an aggressive treatment approach is used for disease control. In this report, we describe a 75-year-old woman with a left ovarian lymphangioma that increased in size during the menopause period. Microscopic examination of the tumor showed thin-walled multilocular cystic spaces and immunoreactivity for D2-40, a specific marker for lymphatic endothelium, lining the cystic spaces. The patient has been doing well for 5 years postoperatively. Ovarian cystic lymphangioma should be included in the differential diagnosis of an ovarian cyst and long-term follow-up is recommended to exclude malignant behavior. We also summarize a total of 25 cases, including the case presented here.*

**Keywords:** Lymphangioma, ovary, Immunohistochemistry, D2-40

Lymphangiomas are rare tumors of the deep (other than cutaneous) lymphatic system that are composed of multiple cystic spaces lined by endothelium (1). These tumors are often the result of congenital malformation of the lymphatic system in children and have rarely been found in adults. Although the most common sites are

the head and neck, lymphangiomas have also been reported in the proximal extremities, mediastinum, retroperitoneum, intestines, pancreas, bowel mesentery, and female genital tract (2-4). A literature search revealed 24 cases of ovarian lymphangioma identified since Kroemer's original description (2,3,5-25). Because of its rareness, the pathogenesis is not clear, the diagnosis is uncertain preoperatively, and little is known about the clinical behavior. In addition, ovarian lymphangioma is often characterized by large size, ascites, or disease recurrence. Therefore, ovarian lymphangioma should be differentially diagnosed and carefully reviewed for optimal care. In this report, we present a case of ovarian lymphangioma and summarize clinical findings of a total of 25 cases.

### CASE REPORT

A 75-year-old woman (gravida 5, para 3) with a history of hepatic segmentectomy 5 years previously presented with incidental left ovarian cyst. Enhanced abdominopelvic computed tomography showed a 4.4-cm thin-walled cystic mass in the left external iliac region that increased in size over 1 year and no associated adenopathy (*Fig. 1*). Serum levels of CA125 and CA19-9 were normal whereas the carcinoembryonic antigen (CEA) tumor marker was elevated to 5.61 ng/mL (normal range: 0-3.4). The patient underwent laparoscopic left salpingo-oophorectomy. In operative findings, the left ovarian cyst had

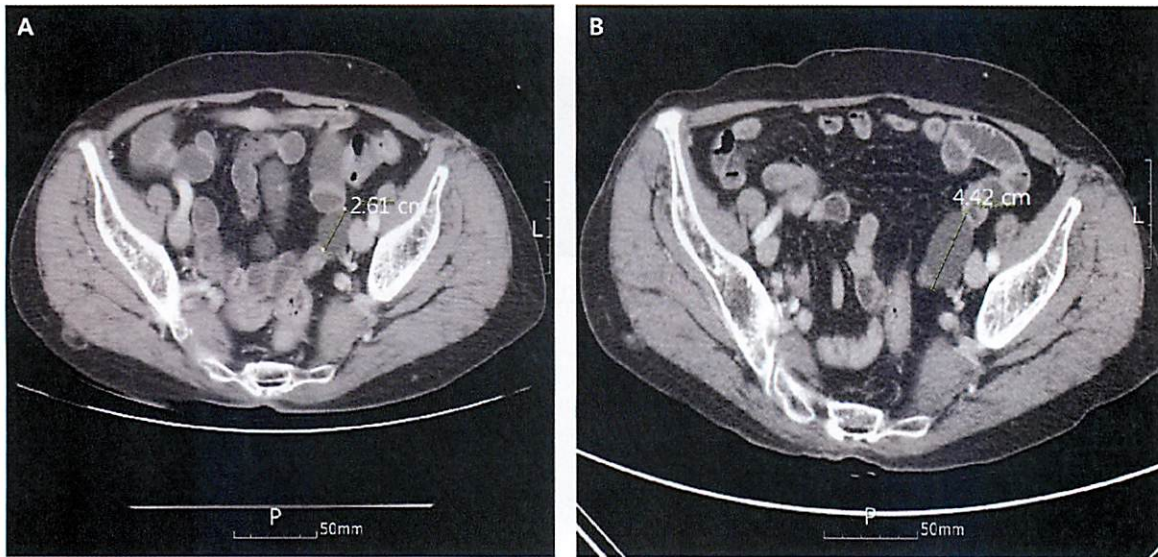


Fig. 1. Abdominal-pelvic CT demonstrates enlargement of left adnexal cystic mass (bar) from 2.61 cm (A) to 4.42 cm (B) over a 1-year period.

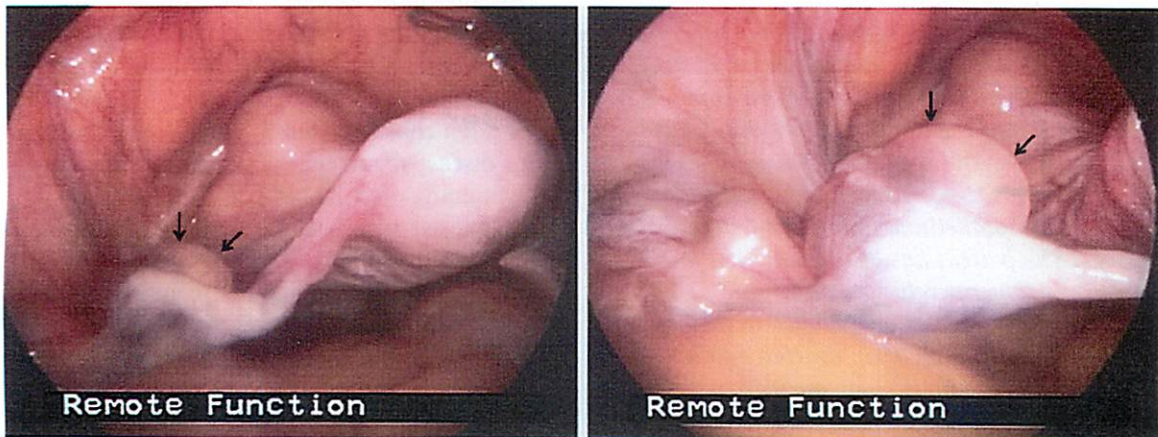


Fig. 2. Laparoscopic images of lymphangioma (arrows) originating from left ovary.

internal septations (Fig. 2) and contained a clear pale fluid. The right ovary and uterus were unremarkable. Examination of a frozen section indicated a benign tumor. The patient's postoperative course was uneventful and no recurrence has been noted after a follow-up of 5 years.

Macroscopically, the specimen was a piece of pale whitish membranous tissue. Microscopic examination showed thin-walled and multilocular cystic spaces in the medulla

and hilus of the ovary. Dilated spaces were lined by flattened endothelium, in which mitosis, pleomorphism, or intraluminal or extraluminal endothelial proliferations were not observed. Immunohistochemical staining with the ultravision LP detection system (Lab Vision, CA, USA) showed that the cells lining the cystic space were immunoreactive for D2-40 (diluted 1:40; Abcam, UK), confirming lymphangioma (Fig. 3).



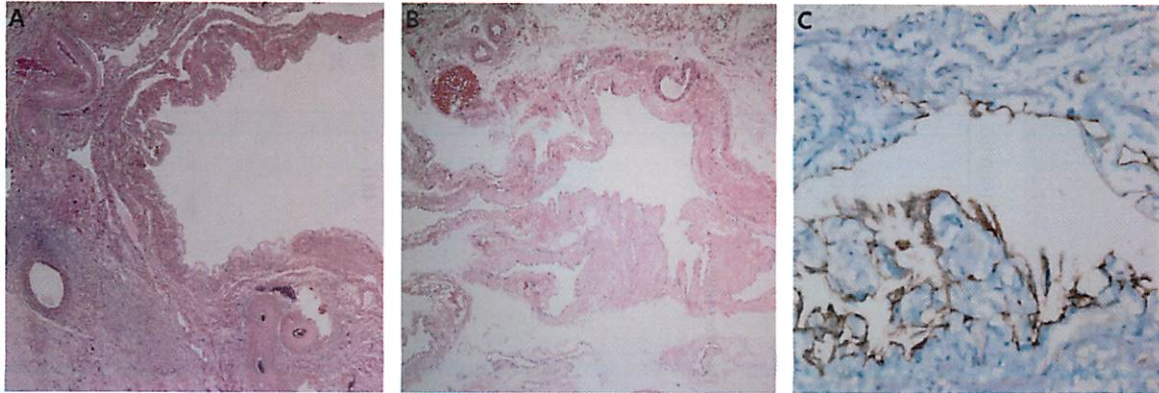


Fig. 3. Thin-walled multilocular cystic spaces were present in medulla and hilus of the ovary. A) hematoxylin-eosin stain (original magnification x40). B) Higher magnification showing that the dilated spaces were lined by flattened endothelium (hematoxylin-eosin stain; original magnification x100). C) The cells lining the cyst space were immunoreactive for D2-40 (hematoxylin-eosin background stain; original magnification x400).

## DISCUSSION

Since the first description by Kroemer in 1908 (2), a total 25 cases of ovarian lymphangiomas, including our case, have been reported (2,3,5-25) and are summarized in Table 1. The age at diagnosis for 21 informative cases ranged from 0 to 75 years (mean, 38.9 years). Two cysts found during prenatal examination at 33 weeks gestation and were removed 4 and 15 days after full-term delivery because of torsion and size increase, respectively (15,19). Among the 20 cases with information on cyst site, most of the ovarian lymphangiomas were unilateral (17/20, 85.0%; 8 in right, 9 in left) and only 3 were bilateral. The affected ovary ranged in size from 3.5 cm to 15 cm (mean 5.95 cm). Two cysts were excluded from measurement of mean size because they were described as a fetal head and twice the size of a child's head; if these were included in size measurements, the mean size of the cyst would be larger. The surgical procedure was unilateral salpingo-oophorectomy in 10 women, hysterectomy with bilateral salpingo-oophorectomy in 9, tumor excision in 1, and unknown in 5. Of particular interest, two cases recurred, two cases were accompanied by milky ascites

upon operation, and one case developed after radiation therapy.

Lymphangiosarcoma arising in lymphangioma is exceedingly rare and thus, primary ovarian malignancies, cystic peritoneal mesothelioma and pseudomyxoma peritonei should be excluded before its diagnosis. Nevertheless, malignant transformation of ovarian lymphangioma was suggested in Kroemer's original report (2) in which the cyst size was large (up to twice the size of a child's head) and advanced necrosis and cystic degeneration was observed. Two recurrent cases were subsequently reported. One case was left ovarian lymphangioma, and complete resection was performed; the patient returned 6 months later with a metastasized lymphangiomas in the right ovary with diffuse intraperitoneal dissemination and hepatic metastasis. She died soon afterwards and postmortem examination showed thick endothelium consisting of intra- and extraluminal proliferations with swelling, necrosis, and hyperchromatic nuclei (7). The other case had local recurrence twice on the same side within 2 years of the original resection. The recurred lesion had the same benign histologic appearance as the original lesion but ultimately the patient required

**TABLE 1**  
**Summary of 25 Cases of Ovarian Lymphangioma from the Literature**

	Age (years)	Site	Diameter (cm)	Operation	Staining	Characteristics	F/U (month)	Reference
1	ND	ND	Fetal head size	ND	ND	Necrosis and cystic generation		2
2	ND	ND	Twice the size of a child's head	ND	ND	Malignant sarcomatous transformation		2
3	ND	ND	7.0	ND	ND	NS		5
4	40	Left	8.0	STH, BSO	ND	NS	22.0	6
5	31	Left	15.0	USO	ND	Recur	6.0	7
6	10-14	ND	ND	ND	ND	NS		25
7	27	Right	4.0	USO	CD31, Factor VIII	Recur	46.0	8
8	35	Right	6.0	USO	ND	NS		9
9	40	bilateral	ND	TAH, BSO	ND	NS		10
10	53	Bilateral	Right: 3.5 Left: 6.0	STH, BSO	Factor VIII(+), CD34(+), CD31(+), Vimentin(+), Keratin (-)	Previous bilateral fimbriectomy	5.0	11
11	48	Right	6.0	TAH, BSO, partial omentectomy	ND	NS		12
12	57	Left	2.8	USO	Factor VIII(+), CD31(+)	NS		3
13	19	Left	4.4	Tumor excision	CD31(+)	After radiation	18	13
14	31 months	Right	8.0	USO	CD31(+), CD34(-)	NS	7.0	14
15	GA 33 weeks	Left	4.8	USO	Factor VIII(+), CD34(+), CD31(+)	Torsion+		15
16	61	Left	9.0	TAH, BSO	CD31(+)	NS		16
17	43	Right	4.1	ND	ND	Milky ascites		17
18	40	Right	7.0	TAH, BSO	Factor VIII (+)	NS		18
19	GA 33 weeks	ND	7.0	USO	Factor VIII(+), CD34(+)	NS	48.0	19
20	42	Right	4.0	TAH, RSO	CD34(+), CD31(+), Vimentin (-), Keratin(-)	NS		20
21	52	Left	6.7	USO	ND	Milky ascites		21
22	29	Left	5.4	USO	CD31(+)	NS		22
23	50	Bilateral	Right: 4.0 Left: 3.5	TAH, BSO	CD31 (+), Factor VIII(+), D2-40(+), CD34(-)	NS		23
24	72	Right	6.3	TAH, BSO	ND	ND		24
25	75	Left	4.4	USO	D2-40(+)	NS	60.0	

ND, not described; NS, non-specific; F/U, follow-up; STH, subtotal hysterectomy; BSO, bilateral salpingo-oophorectomy; USO, unilateral salpingo-oophorectomy; TAH, total abdominal hysterectomy; GA, gestational age

low-dose radiation therapy to control the disease suggesting that clinical behavior cannot be predicted even in the case of benign histologic findings (8). These cases warn of the possibility of malignant transformation of ovarian lymphangiomas and indicate that patients with ovarian lymphangioma should be followed up carefully.

Because of the paucity of cases and the lack of specific imaging findings, lymphangiomas of the ovary are hard to diagnose preoperatively. Therefore, they require precise differentiation from other more common ovarian cysts through careful histopathologic examination, and special attention should be paid to possible transformation to malignancy. In 12 cases, including the one presented here, immunohistochemical staining was used in conjunction with histopathology to differentiate tumors of the ovary. Initial studies reported the use of five antibodies targeting factor VIII-related antigen, CD34, CD31, vimentin, and low molecular weight keratin (11). The cells lining the cystic spaces of the lymphangioma were immunoreactive for factor VIII-related antigen, CD34, CD31, and vimentin, but not for low molecular weight keratin. Of the five, CD31 and CD34 are known to be specific markers for endothelial cells, highlighting both blood vessels and lymphatic endothelium. In contrast, D2-40 targets human podoplanin, a mucin-type transmembrane protein of lymphatic endothelial cells, and is a special marker for lymphatic differentiation in the vascular context. D2-40 is widely used for a variety of lymphovascular neoplasms such as lymphangioma, Kaposi sarcoma, and hemangioendothelioma (26,27). Two studies, including ours, used D2-40 to distinguish lymphangioma.

In summary, we have added a new case of ovarian lymphangioma to the limited number of reported cases. Our patient is the oldest reported to date, has a longer follow-up, and was diagnosed with D2-40. We summarize the clinical findings of our case and 24 previously reported cases. For a more

accurate prediction of the natural history of ovarian lymphangioma, additional case reports with extended follow-up should be continuously accumulated.

#### ACKNOWLEDGMENT

This study was supported by a grant from the Basic Science Research Program through the National Research Foundation of Korea (NRF) funded by the Ministry of Education (2013R1A1A2009971).

#### REFERENCES

1. Enzinger FM, SW Weiss: *Soft Tissue Tumor*. Mosby, St Louis, MO, 1988.
2. Kroemer, L: *Handbuch der gynäk.* Bergmann, Weisbaden, Germany, 1908.
3. Kearney, CE, GH Hall, DW Purdie, et al: Ovarian lymphangioma: MRI appearances. *Clin. Radiol.* 56 (2001), 685-687.
4. Levy, AD, V Cantisani, M Miettinen: Abdominal lymphangiomas: Imaging features with pathologic correlation. *AJR Am. J. Roentgenol.* 182 (2004), 1485-1491.
5. Fleisher, R: Malignant lymphangioma of the ovary. *Monatsschrift für Geburtshilfe und Gynäkologie.* 62 (1923), 45-49.
6. Siddall, RS, WR Clinton: Lymphangioma of the ovary. *Am. J. Obstet. Gynecol.* 34 (1937), 306-310.
7. Rice, M, B Pearson, WB Treadwell: Malignant lymphangioma of the ovary. *Am. J. Obstet. Gynecol.* 45 (1943), 884-888.
8. Aristizabal, SA, JH Galindo, JR Davis, et al: Lymphangiomas involving the ovary. Report of a case and review of the literature. *Lymphology* 10 (1977), 219-223.
9. Khanna, S, ML Mehrotra, MK Basumallick: Lymphangioma cavernosum of the ovary. *Int. Surg.* 63 (1978), 104-105.
10. Logani, KB, K Agarwal: Lymphangioma of the ovary. *J. Indian. Med. Assoc.* 95 (1997), 146-152.
11. Evans, A, A Lytwyn, G Urbach, et al: Bilateral lymphangiomas of the ovary: An immunohistochemical characterization and review of the literature. *Int. J. Gynecol. Pathol.* 18 (1999), 87-90.
12. Ahluwalia, J, V Girish, S Saha, et al: Lymphangioma of the ovary. *Acta. Obstet. Gynecol. Scand.* 79 (2000), 894-895.
13. Heinig, J, V Beckmann, T Bialas, et al: Lymphangioma of the ovary after radiation

- due to Wilms' tumor in the childhood. *Eur. J. Obstet. Gynecol. Reprod. Biol.* 103 (2002), 191-194.
14. Sabaratnam, RM, L Mogotlane, R Chetty: Primary ovarian lymphangioma in a child. *J. Gynecol. Surg.* 19 (2003), 97-101.
  15. Park, C, JW Lee, SJ Kim, et al: Sonographic findings of prenatal torsion of ovarian lymphangioma. *J. Clin. Ultrasound.* 33 (2005), 421-423.
  16. Akyildiz, EU, D Peker, S Ilvan, et al: Lymphangioma of the ovary: A case report and review of the literature. *J. BUON.* 11 (2006), 91-93.
  17. Iwasa, T, A Tani, Y Miyatani, et al: Lymphangioma of the ovary accompanied by chylous ascites. *J. Obstet. Gynaecol. Res.* 35 (2009), 812-815.
  18. Jain, D, V Saroha, M Singh: Lymphangioma of the ovary. *J. Obstet. Gynaecol.* 29 (2009), 260-261.
  19. Jallouli, M, L Trigui, N Gouiaa, , et al: Neonatal ovarian lymphangioma. *J. Pediatr. Adolesc. Gynecol.* 24 (2001), e9-e10.
  20. Kafeel, G, PU Telisinghe, H Oo: Lymphangioma of the ovary. *Brunei. Int. Med. J.* 6 (2010), 145-148.
  21. Singer, T, G Filmar, S Jormark, et al: Rare case of ovarian cystic lymphangioma. *J. Minim. Invasive. Gynecol.* 17 (2010), 97-99.
  22. Barvikar, RR, C Tampi: Lymphangioma of ovary. *Bombay Hosp. J.* 53 (2011), 89-91.
  23. Pillai, S, D O'Brien, CJ Stewart: Bilateral ovarian lymphangioma (lymphangioleiomyoma). *Int. J. Gynecol. Pathol.* 32 (2013), 171-175.
  24. Naik, SA: Rare case of ovarian cystic lymphangioma managed at laparoscopy. *J. Gynecol. Endosc. Surg.* 2 (2011), 97-100.
  25. Norris, HJ, RD Jensen: Relative frequency of ovarian neoplasms in children and adolescents. *Cancer* 30 (1972), 713-719.
  26. Ordonez, NG: Podoplanin: A novel diagnostic immunohistochemical marker. *Adv. Anat. Pathol.* 13 (2006), 83-88.
  27. Kalof, AN, K Cooper: D2-40 immunohistochemistry-so far! *Adv. Anat. Pathol.* 16 (2009), 62-64.

**Eun-Ju Lee, MD, PhD**  
**Department of Obstetrics and Gynecology**  
**Chung-Ang University School of Medicine/**  
**Chung-Ang University Hospital**  
**224-1, Heuksuk-Dong, Dongjak-Gu,**  
**Seoul, 156-755, Korea**  
**TEL: 82-2-6299-1648**  
**FAX: 82-2-6263-2187**  
**E-mail: ejlee@cau.ac.kr**