

TECHNICAL NOTES

An Improved Method for Attaching the Esophageal Fistula Bag

R.J. KARTCHNER AND D.C. ADAMS

Abstract

A simple, surgically established skin "neck loop" was tested for holding the collection bag in position on esophageal fistulated steers. The loop eliminated the need for a girth strap and reduced the time required for attaching and detaching the collection apparatus.

The esophageal fistula has been used for many years to collect forage samples representative of the grazing animal's diet (Van Dyne and Torell 1964). The usual method for attaching the collection bag involves suspending the bag from the neck with two straps and tying it back to a girth strap to prevent the bag from slipping forward when the animal lowers its head to graze (Fig. 1). This system has generally been satisfactory. However, some of our work has involved as many as 12 esophageal fistulated steers at one time. A means was sought to eliminate the need for the girth strap for holding the bag in position, as this contributes substantially to the time required to attach and detach the collection bag.

Procedure

To accomplish our objective, a skin "loop" was surgically established along the top of the neck just anterior to the top of the shoulder (Fig. 2). In preparation for surgery, the animal received a general tranquilizer, and the immediate surgical area was infused with a 2.5% procaine solution. Two parallel incisions 4-5 cm apart were made along the top of the shoulder and neck (Fig. 3). The incisions extended anteriorly approximately 10 cm from a point even with an imaginary line connecting the highest points of the shoulder blades. The strip of skin between the incisions was separated from underlying connective tissue and the edges of the strip folded under

Authors are research animal scientists, USDA Agriculture, Agricultural Research Service, Miles City, Mont. 59301.

This report is a contribution from the USDA Agricultural Research Service, in cooperation with Montana Agricultural Experiment Station, Journal Series No. 1213 and was contributed to Western Regional Project W-151.

Manuscript received November 6, 1981.




Fig. 1. Esophageal fistula bag showing conventional girth strap arrangement.



Fig. 2. Neck loop on esophageal fistulated steer.

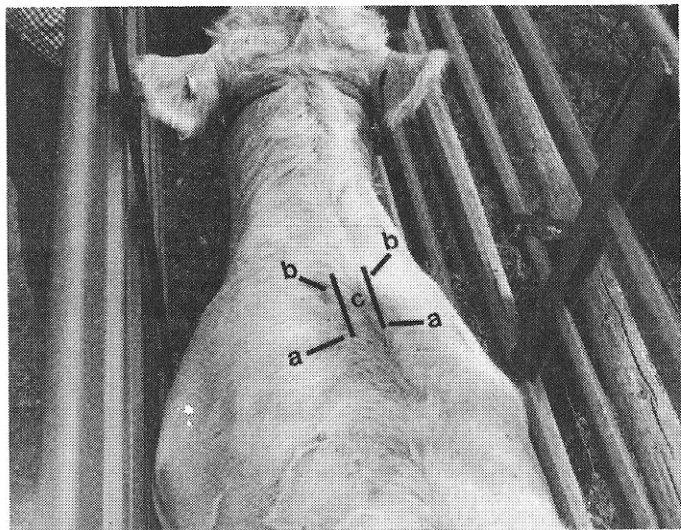


Fig. 3. Dorsal view of neck and shoulders showing: (a) top of shoulders; (b) incision; (c) median skin strip that forms loop.

and sutured together forming the loop. The remaining skin edges were then drawn together beneath the loop and sutured. Following surgery, a penicillin-dihydrostreptomycin solution was infused around and under the sutures, and an intramuscular injection of the antibiotic was given according to the manufacturer's recommendations. Post-operative care included periodic application of petroleum jelly to reduce scab formation for 1 to 2 weeks and antibiotic treatment if evidence of infection was found. Careful observation of the animals following surgery indicated no evidence of undue discomfort resulting from the operation, and no problems of infection were encountered. The sutured areas healed rapidly, although the scar tissue remained tender for a period of time following surgery.

To attach the collection bag, the posterior strap suspending the bag was slipped through the loop (Fig. 4). This prevents the strap from slipping forward when the animal's head is lowered, thus eliminating the need for a girth strap.

Discussion

Neck loops were established on 3 steers to test the concept. Collections were made using the loops approximately 2 months

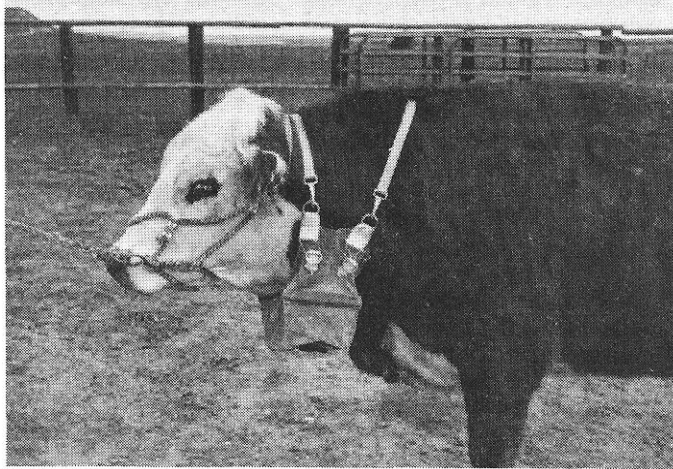


Fig. 4. Esophageal fistulated steer with collection bag supported by neck loop.

post-surgery. At that time, the wounds were fully healed, but the scar tissue was still tender and subject to chafing and sore formation due to the rubbing of the strap. When this happened, the animal ceased to graze, as the act of lowering the head increased the chafing on the scar tissue, and weight due to filling the bag with ingesta increased pressure on the neck.

After a 6-month period, the loops were tested again. At this time, there were no apparent problems of chafing and sore formation, even after repeated collections. Steers grazed normally and showed no signs of discomfort, even when collection bags were full. It is probable that the loop could be used sooner by providing a pad to prevent chafing by the support strap.

Our experience and observations suggest the following advantages to using the neck loop compared to the conventional girth strap: (1) the surgical procedure is relatively simple and, once established, the loop is permanent and maintenance free; (2) fewer straps required mean less chance of snagging on limbs or fences; and (3) less time is required to attach and detach the collection apparatus.

Literature Cited

Van Dyne, G.M., and D.T. Torell. 1964. Development and use of the esophageal fistula: a review. *J. Range Manage.* 17:7-19.